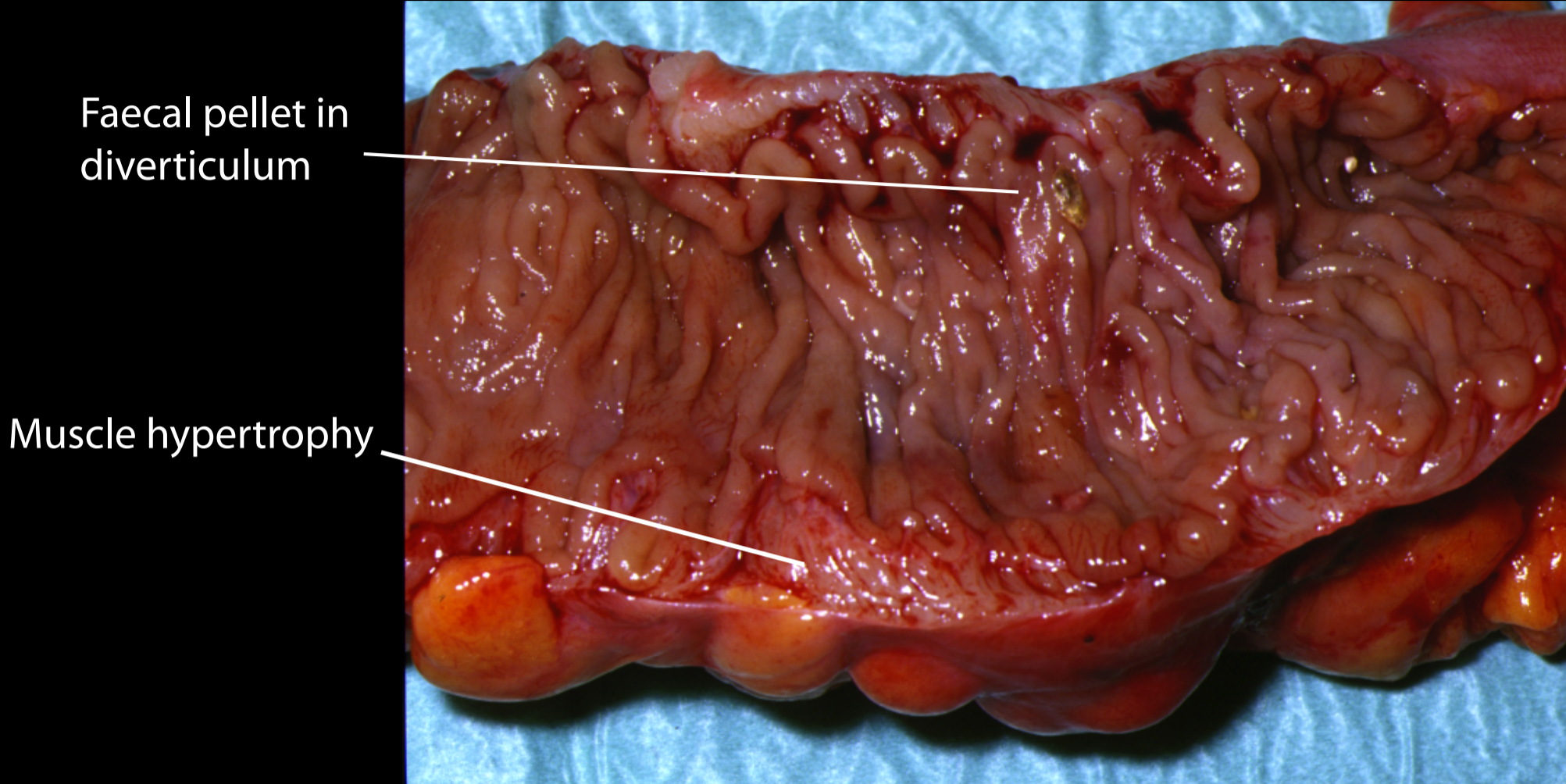


Diverticular stricture

Surgical specimen and barium enema of the same patient.



Barium enema showing multiple diverticula and a long stricture

